

Sir,
Peripheral retinal neovascularization in bullous central serous chorioretinopathy

Central serous chorioretinopathy (CSC) may present in many different ways, including the typical patterns of localized pocket of subretinal fluid, serous pigment epithelium detachment (PED), combined subretinal fluid and PED. The less common manifestations include CSC with multiple leakages, diffuse retinal pigment epitheliopathy, chronic CSC with subtle leakage, gravitational epitheliopathy (RPE tract), bullous retinal detachment, dense subretinal fibrinous deposition, cystoid macular oedema, choroidal neovascularization, massive haemorrhage, and retinal telangiectasia.¹ Peripheral retinal neovascularization in CSC, however, is a truly rare presentation and may deceptively mimic other intraocular inflammatory diseases. Here, we reported two cases of bullous CSC presenting with peripheral retinal neovascularization and both had been treated initially as retinal vasculitis and choroiditis respectively with oral prednisolone.

Case reports

Case 1: A 45-year-old Chinese man with an unremarkable medical history presented with a drop in vision in his both eyes. Fundus examination revealed bilateral bullous retinal detachment and left inferior perivascular exudates and retinal neovascularization (Figure 1a and b). Systemic work-up was negative and he was managed as idiopathic retinal vasculitis with oral prednisolone given for 2 months. His exudative retinal detachment got worse and was then referred for management. The best-corrected visual acuity (BCVA) at that time was 20/400 in each eye. The anterior segment and anterior vitreous were quiet. Fundus examination revealed bilateral bullous retinal detachment in both eyes with abnormally occluded retinal vessels in the inferior peripheral retina of the left eye. Fluorescein angiography (FA) revealed multiple diffuse hyperfluorescence areas in both posterior poles corresponding to the multiple leakage areas at the level of retinal pigment epithelium. Capillary nonperfusion, abnormally dilated telangiectatic retinal vessels, and tufts of retinal neovascularization were obvious in the early phase of the FA of his left eye (Figure 1c). Profuse fluorescein leakages from the retinal bridging collaterals and neovascularization were seen in the late phase of FA (Figure 1d). The diagnosis was revised to chronic CSC, rather than intraocular inflammatory disease, in considering multiple RPE leakages, generalized atrophic RPE window defects, bullous RD, absence of vitritis, or other inflammatory features.

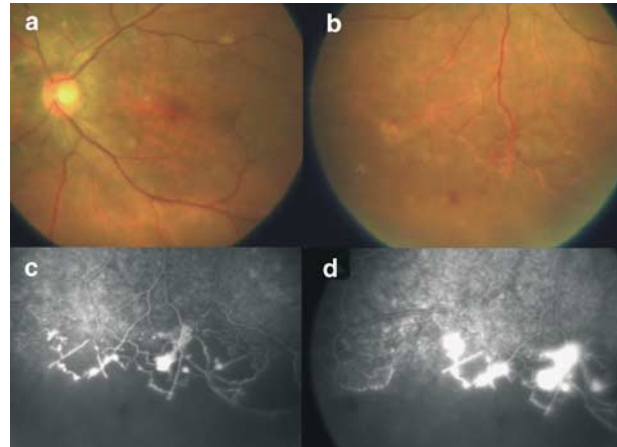


Figure 1 Left eye of the case 1 with chronic central serous chorioretinopathy. (a) Colour fundus photograph shows diffuse pigmentary changes at the retinal pigment epithelium layer in the posterior pole. (b) Fundus photograph reveals inferior retinal detachment with abnormal telangiectatic retinal vessels and perivascular exudates. (c) Early phase of the FA shows capillary dropout, retinal telangiectasia, and tufts of retinal neovascularization. (d) Late phase of the FA demonstrates profuse fluorescein leakages from the abnormal retinal vessels.

Steroid was then stopped. Reassurance on the nature of the disease and avoidance of emotional stress had been emphasized. It took 2 months for the subretinal fluid to be totally absorbed. The BCVA at 12 months later was 20/100 in his right eye and 20/200 in the left eye. The abnormal peripheral vascular changes and neovascularization had regressed and left behind generalized RPE mottling in both eyes.

Case 2: A 39-year-old Chinese male with good past health presented with bilateral blurring of visions for 6 months and had been treated by other doctors as having choroiditis and vasculitis with oral prednisolone. In April 2001, his BCVA was HM in his right eye and 20/400 in his left. Both anterior and vitreous spaces were clear. Fundus examination revealed an exudative retinal detachment with shifting signs and dense subretinal exudative deposits in both eyes (Figure 2a). Narrowing and telangiectatic changes of the peripheral retinal vessels were noticed over the inferior retina of both eyes. Peripheral retinal neovascularization was recognized in his right eye. FA showed multiple focal leakages at the posterior poles of both eyes and capillary dropout (Figure 2b), leakages from telangiectatic vessels within inferior part of retina (Figure 2c). Sea-fan retinal neovascularization with profuse angiographic leakages was seen in the late phase FA of the right eye (Figure 2d). The diagnosis of chronic CSC was made and the steroid was tapered. The subretinal fluid resolved gradually and was completed in 3 months. The final vision checked 18

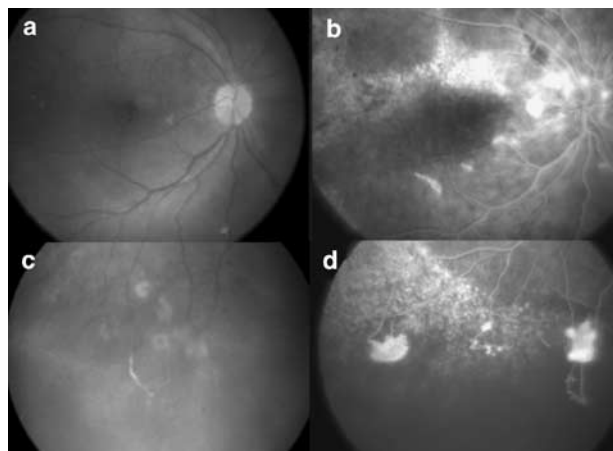


Figure 2 Right eye of case 2 with chronic central serous chorioretinopathy. (a) Colour fundus photograph of the right eye shows focal pigmentary changes of the retinal pigment epithelium. (b) FA showed multiple focal leakages and window hyperfluorescence at the posterior pole of right eye. (c) Fundus photograph of the right eye shows inferior dependent retinal detachment with retinal neovascularization. (d) FA of the corresponding retina demonstrates loss or peripheral retinal vessels, telangiectasis, and retinal neovascularization with leakage in the mid-phase.

months later was HM in his right eye and 20/100 in his left eye.

Comment

Peripheral retinal neovascularization may develop over ischaemic retina secondary to metabolic diseases, radiation retinopathy, primary vascular abnormalities, haemoglobinopathy, localized inflammation, infection, tumour or degenerative diseases. Chronic rhegmatogenous retinal detachment may rarely be associated with peripheral retinal vascular changes including telangiectasia and retinal neovascularization.²

Yannuzzi *et al*¹ had reported secondary vascular changes of the retina in cases of chronic or gravitational CSC with features of dilated and telangiectatic peripheral capillaries. CSC-associated retinal neovascularization had hardly been reported in the literatures. Akiyama *et al*³ had documented similar finding in a patient with chronic bullous CSC and Gass⁴ separately also reported comparable observation in another patient with bullous CSC, who was initially diagnosed as retinoschisis and uveal effusion syndrome for 5 years prior to the exact diagnosis. The pathogenesis for this kind of retinal neovascularization is still unclear but may be related to ischaemic changes in chronic detachment through the release of angiogenesis factors from the affected retina and RPE cells.

Bullous CSC occasionally mimics other ocular diseases such as rhegmatogenous retinal detachment, retinoschisis, Harada disease, uveal effusion, and malignancy. The concomitant retinal neovascularization, perivascular, and subretinal exudates may cause further confusions with choroiditis, retinal vasculitis and Eales' disease.⁵ Wrongly prescribed corticosteroids may sometimes cast an undue adversity on the course and outcomes of the disease, as reflected in our patients.

Typical demographic and clinical features of CSC including young to middle-age male subjects bilateral presentations, shifting subretinal fluid, subretinal fibrinous exudates, clear aqueous humor and vitreous, and multiple and diffuse areas of fluorescein leakages, gravitating tract should be watched out with vigilance. In case of doubt, the use of indocyanine green angiogram may be helpful.⁵ The final visual prognosis is, in general, related to the duration of the retinal detachment, healthiness of the RPE, and any formation of submacular fibrosis. Retinal neovascularization usually regressed upon the reattachment of the retina. Therefore, avoidance of any forms of steroid and emotional events are deemed important and patients should be constantly advised with regard to those aspects. If the subretinal fluid persists, prompt focal or grid laser photocoagulation on extrafoveal leaking sites or oral acetazolamide may be considered in expediting the course of visual recovery.⁴

References

- 1 Yannuzzi LA, Shakin JL, Fisher YL, Altomonte MA. Peripheral retinal detachments and retinal pigment epithelial atrophic tracts secondary to central serous pigment epitheliopathy. *Ophthalmology* 1984; **91**: 1554–1572.
- 2 Felder KS, Brockhurst RJ. Retinal neovascularization complicating rhegmatogenous retinal detachment of long duration. *Am J Ophthalmol* 1982; **93**: 773–776.
- 3 Akiyama K, Kawamura M, Ogata T, Tanaka E. Retinal vascular loss in idiopathic central serous chorioretinopathy with bullous retinal detachment. *Ophthalmology* 1987; **94**: 1605–1609.
- 4 Gass JD, Little H. Bilateral bullous exudative retinal detachment complicating idiopathic central serous chorioretinopathy during systemic corticosteroid therapy. *Ophthalmology* 1995; **102**: 37–747.
- 5 Spaide RF, Hall L, Haas A, Campeas L, Yannuzzi LA, Fisher YL *et al*. Indocyanine green videoangiography of older patients with central serous chorioretinopathy. *Retina* 1996; **16**: 203–213.

W-M Chan^{1,2}, DTL Liu¹, CKM Chan², BWC Wong¹, PMK Tam¹ and DSC Lam^{1,2}

¹Department of Ophthalmology and Visual Sciences

Prince of Wales Hospital, Kowloon
Hong Kong
People's Republic of China

²Department of Ophthalmology
and Visual Sciences
The Chinese University of Hong Kong
Hong Kong Eye Hospital, Kowloon
Hong Kong
People's Republic of China

Correspondence:
W-M Chan

Department of Ophthalmology and
Visual Sciences
The Chinese University of Hong Kong
3/F, Hong Kong Eye Hospital
147K Argyle Street Kowloon, Hong Kong
Tel: +852 2632 2879
Fax: +852 2648 2943
E-mail: cwm6373@netvigator.com

Financial Interest: Nil.
Financial Support: Nil.

Eye (2004) **18**, 1275–1277. doi:10.1038/sj.eye.6701399
Published online 30 April 2004

Sir,
Macular infarction a presentation of sickle cell crisis

A 24-year-old black male with sickle cell disease (SCD) 'SS' presented to the emergency room (ER) in sickle cell crisis with acute painless loss of vision OD, chest, and leg pains since one day. His visual acuity was HM OD and J1 OS with 3+ afferent pupillary defect OD. Anterior segment examination was unremarkable. Ophthalmoscopy OD revealed retinal pallor with dilated tortuous vessels. OS fundus was normal. Systemic evaluation revealed icterus with normal pulmonary, cardiovascular, or neurological examination with no history of comorbid conditions. The haemoglobin was 9.6 gm/dl and haematocrit was 27.9%. Exchange transfusion was performed subsequent to hydration.

At 1 week the visual acuity (VA) was HM OD and 20/25 OS. Ophthalmoscopy OD revealed pale, white, thickened retinal lesion centred on the fovea, arterial attenuation, cherry red spot, and pale optic disc (Figure 1 inset). Fluorescein angiography (FA) OD demonstrated

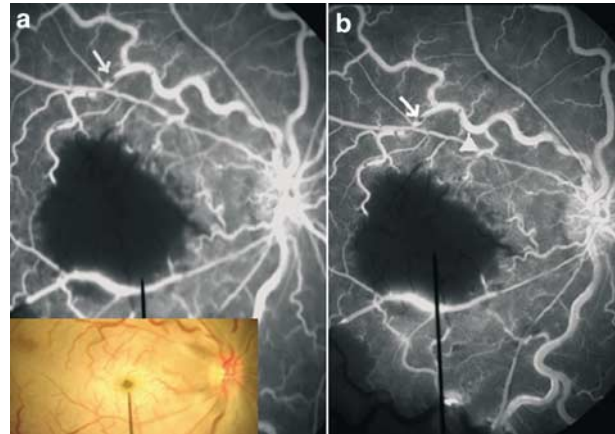


Figure 1 (a) Fluorescein angiogram OD (1 week) early phase showing a marked increase in size of the FAZ due to microvascular occlusion. The white arrow shows that the area of block fluorescence may be due to microemboli. Inset: Photograph of the fundus of the right eye at 1 week. (b) Fluorescein angiogram OD (1 week) late phase showing marked increase in the size of FAZ due to microvascular occlusion. The white arrow shows the area of block fluorescence, while the white arrowhead shows the area of hyperfluorescence (staining) may be suggestive of microemboli and/or slugging of sickled cells with slowed circulation in the venules.

perifoveal arteriole occlusions with enlargement of the FAZ (Figure 1). Vessels had areas of blocked fluorescein in early and late phases (Figure 1a and b), while hyperfluorescein areas (Figure 1b) in the late phases (staining). FA OS was normal.

At 3 months VA was CF 3 feet OD, 20/20 OS. Ophthalmoscopy OD revealed pale disc with marked arterial attenuation and pigmentary changes in the macula (Figure 2a). Macular perimetry (Nidek Technologies, Vigonza, Italy) revealed unstable fixation with absolute macular scotoma OD with normal findings OS (Figure 2b-d). His haemoglobin was 9.5 gm/dl and haematocrit was 26.0%.

Comments

Occlusive disease of the peri-foveal arterioles is known to occur in sickle cell disease.^{1,2} We present a dramatic occlusive event of the macula surrounding the foveal avascular zone, resulting in severe and permanent loss of vision. We are unaware of any previous report of FA showing possible microemboli in the retinal vessels with macular infarction in SCD. Direct sickling may cause occlusion in arterioles or in capillary beds creating a 'log-jam' in the arterioles.³ In this case, the occlusions surrounded the macula from multiple directions, suggesting perifoveal